
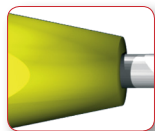




TELEGRAPH®

Mixed Operating Technique
Humerus nail short and long



www.telegraphnail.com



quality for health

TELEGRAPH®

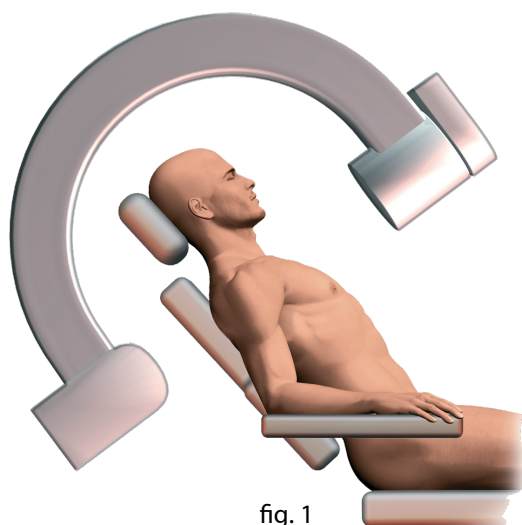


fig. 1

1. COMMON RULES

1.1 Positioning of the patient

The patient is in a semi-seated position. The affected shoulder should extend clearly beyond the edge of the operating table. The forearm should be resting on an arm-rest.

The arm is in 25-30° retraction in relation to the thorax to liberate the point of entry.

The fluoroscope should be placed longitudinally at the level of the patient's head (fig. 1).

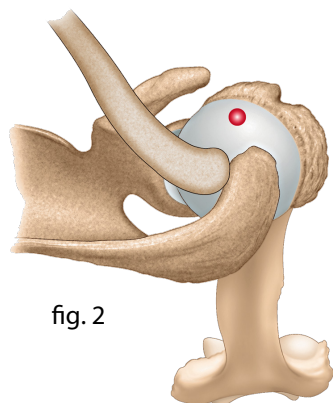


fig. 2

1.2 Point of entry

The point of entry is found at the articular summit of the head of the humerus, in front of the acromion (fig. 2).

The awl square trepanates the head of the humerus (fluoroscope).

A proximal reamer measuring 7, 8 or 9 mm (depending on the diameter of the nail chosen) calibrates the entry opening (fig. 3). The nail and its holder (ref. 253 671 and ref. 253 680) are then introduced (fig. 4).




fig. 3

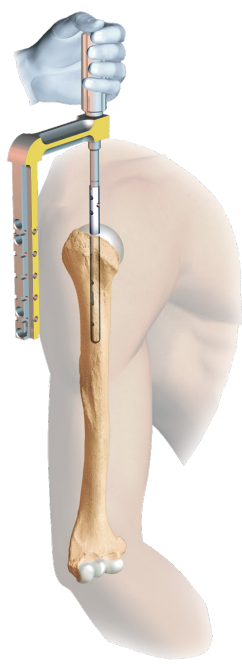


fig. 4

1.3 Length of the nail

The proximal end must imperatively be below the bony articular level of the head of the humerus (fig. 5). Marking with the fluoroscope is necessary.

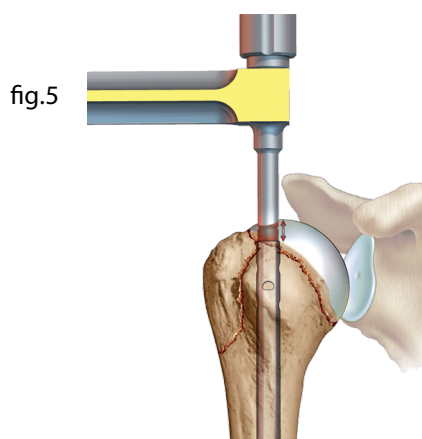


fig. 5

Mixed Operating Technique

Humerus nail Short and Long

AND TECHNIQUES

1.4 Proximal locking

The large and small guides (ref. 253 677, drill sleeve and ref. 253 678, screw-tap sleeve*) make packing possible at 2.5 mm. The graduated drill bit gives the length (40 mm more often than not). The screws are positioned without screw-tapping at the proximal level using the blue-handled small fragment screwdriver (ref. 233 339).

The two mediolateral frontal screws (fig. 6) are essential and stabilise the major tubercle and head of the humerus. The sagittal screw, which is optional, is placed with an extension of the ancillary system (fig. 7, proximal targeting device : 253 672, M5 connective screw : 253 681). This screw is indicated for stabilising the minor tubercle or to perfect the osteosynthesis of the two frontal screws.

1.5 Distal screwing

It is recommended that this be performed dynamically (most distal opening of the ancillary, fig. 8).

The soft-tissue retractor (obturator, ref. 236 844), introduced into the large guide, comes into contact percutaneously with the diaphyseal cortex. The following stages are :

- packing at 2.5 mm ;
- screw-tapping (ref. 233 341), obligatory at this level (cortical bone) ;
- locking.

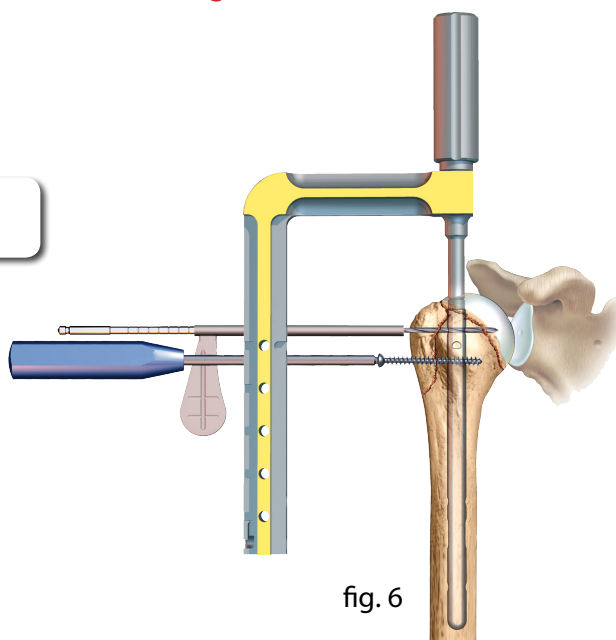


fig. 6

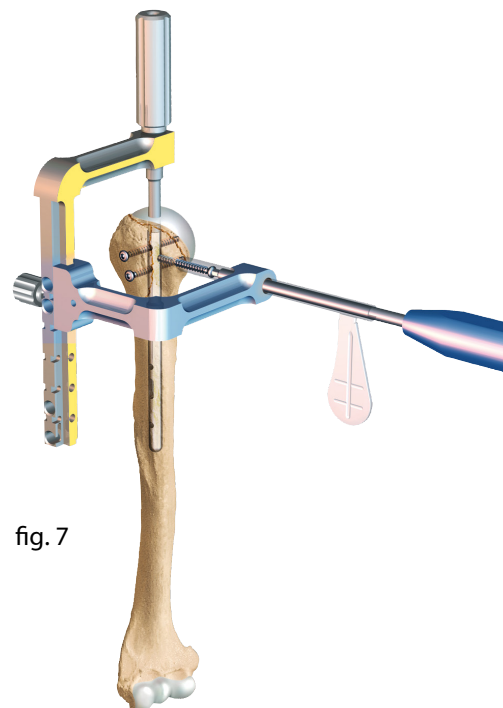


fig. 7

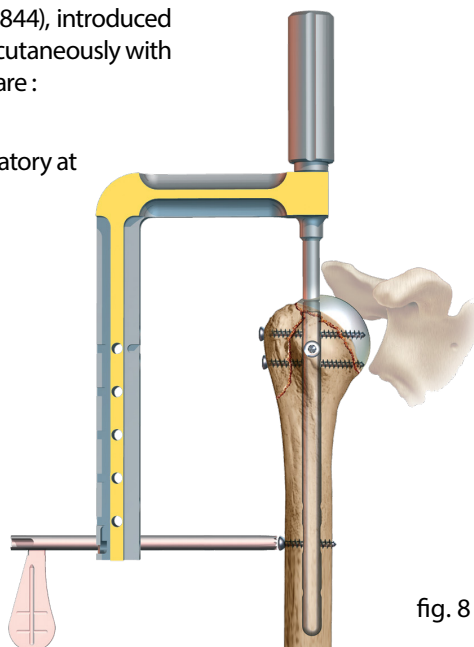


fig. 8

* The tools and their references can be found at the end of this document.

2. SHORT TELEGRAPH[®] NAIL

The short nail has three possible diameters :

7 mm, 8 mm and 9 mm, and a single length of 15 cm.

There are three techniques : percutaneous, standard and cup-and-ball.

The technique to be used must be chosen in relation to the increasing complexity of the fractures.

2.1 The percutaneous technique

>> Extra-articular fractures with two or three fragments.

Prior reduction is imperative, and this can be obtained either by external manœuvres or percutaneously using a spatula or a pin (joystick manœuvre, fig. 8).

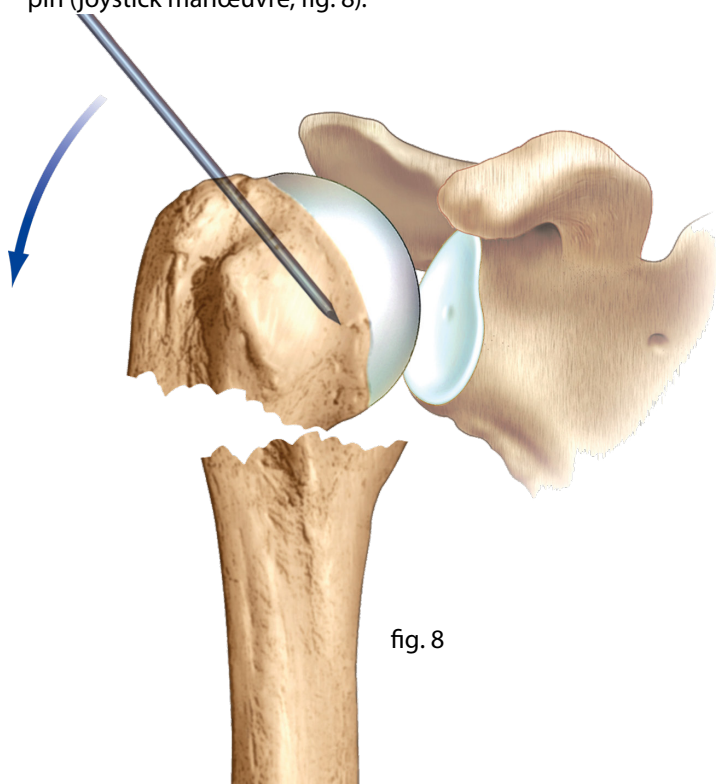


fig. 8

A short pre-acromion incision makes it possible to introduce the blunt scissors until they come into contact with the head of the humerus.

The point of entry of the articular tip of the head can be identified using the fluoroscope with the awl square. This will trepan the head of the humerus.

The soft tissue retractor (ref.236 844) makes it possible to approach the epiphysis so as to position the screws percutaneously.

The following times are those described in §1.4.

Distal locking is optional, though recommended (§1.5).

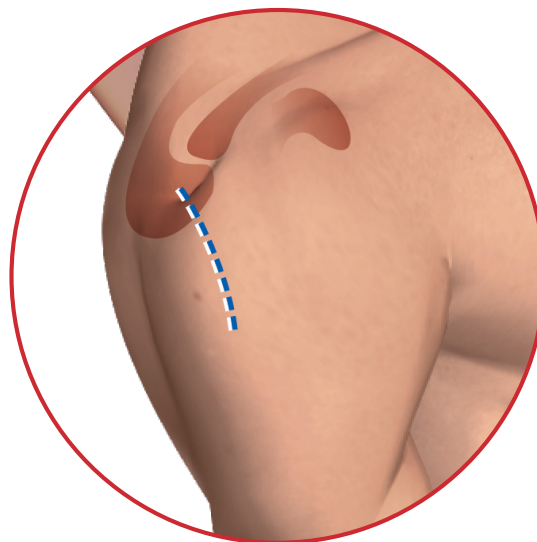


fig. 9

2.2 The standard technique

>> Fractures with 3 non-reducible percutaneous fragments and 4 articular fragments.

The antero-external approach includes the incision and creation of the digastric trapezo-deltoid flap. The incision (fig. 9) measures 8 to 10 cm. It is centred by the antero-external angle of the acromion, 1/3 proximal, 2/3 distal, oriented in the same direction as the fibres of the deltoid.

The digastric trapezo-deltoid flap (fig. 10) is created by dissecting between the middle deltoid and the anterior deltoid with periosteal stripping of the acromion in the same axis. The digastric flap is tilted forwards, bringing with it the acromioclavicular ligament. This approach is direct for the various fragments and, in particular, the tuberosities (fig. 11).

The fragments are reduced using a spatula, a Lambotte hook or external manœuvres.

More often than not, the head is pushed backwards. Knowing how to reduce it is essential.

When reduction is difficult, it is possible to use a technique known as the "crucifixion technique" (fig. 12). This consists in pinning the head of the humerus into its anatomical position, against the glenoid.

Once reduction has been obtained, the nail can be installed in the usual manner (§1.2, §1.3, §1.4, §1.5).

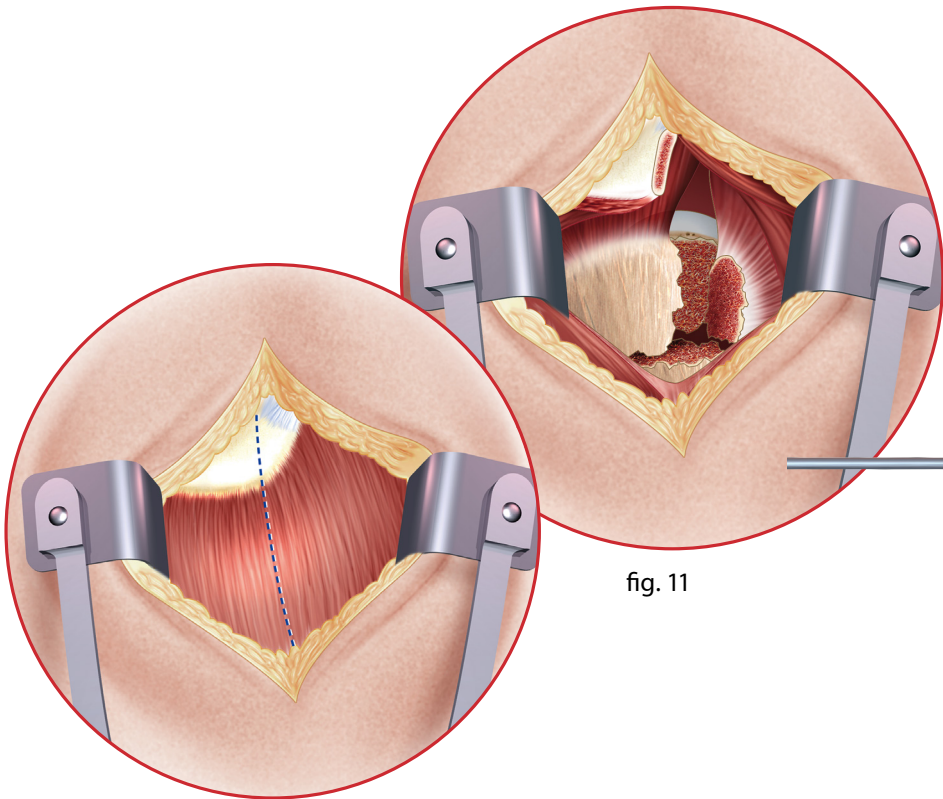


fig. 10

fig. 11

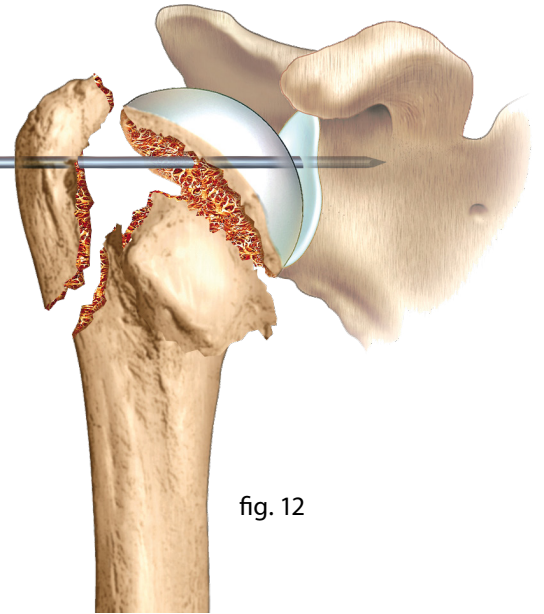


fig. 12

2.3 The cup-and-ball technique

>> Complex articular fractures.

Difficult surgery. Not to be attempted without a certain amount of experience with this material.

The installation of the patient and antero-external approach are standard (§1.1 and 2.2). The nail is positioned, along with its holder, without reduction of the fragments. It is screwed into place distally (fig. 13) using a static screw.

The nail-holder is dismantled. The following stages consist in reducing the head of the humerus directly on to the proximal part of the nail. It is then screwed (fig. 14) on to the nail with two screws. The tuberosities, identified on the threads, are reduced and osteosutured to the head, to each other, to the nail and to the proximal part of the diaphysis. (fig. 15)

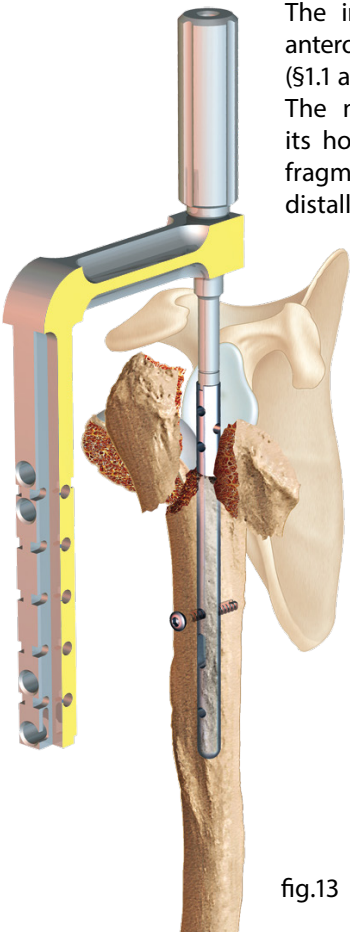


fig.13

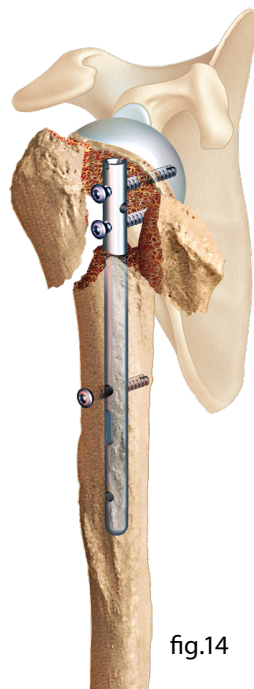


fig.14

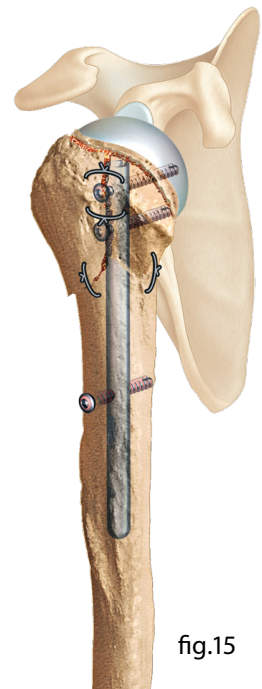


fig.15

3. LONG TELEGRAPH[®] NAIL

The long nail has two diameters : 7 mm and 8 mm, and four lengths : 21, 23, 25 and 27 cm.

3.1 Installation of the nail and proximal locking

The installation and point of entry are standard. Except under particular circumstances, the percutaneous technique is used (§1.1, 1.2, 2.1). The 7 and 8 mm, rigid, graduated, manual reamers, used as far as the distal humeral fragment, make it possible to determine both diameter and length (fig. 16). The nail, mounted on its nail-holder (fig. 17), is introduced. Passing the fracture site is typically easy. Setting the length and proximal locking are standard (§1.3 and 1.4).

3.2 Installation of the intermediate positioner

The aim is to rigidify the nail-holder for the distal guide. The soft tissue retractor (intermediate obturator - ref. 253 676) used in the small guide (notched blue, ref. 253 679, short guide) makes it possible to arrive, through the distal guide opening, in contact with the humerus. The following stages consist in drilling the external cortex with a grey drill bit with abutment (fig. 18, ref. 254 033). All that then remains is to put the intermediate positioner (fig. 19, ref. 253 675) into its notch, leaving the small guide in place.

3.3 Distal locking

Two coloured branches for the distal guide are available. Yellow for the right side (ref. 253 674, right distal targeting device) and blue for the left side (left distal targeting device, ref. 253 673). They are joined using an M5 connective screw (ref. 253 681) on the main beam, on the side of the band in the same colour, at the level of the length mark of the nail (nail holder, ref. 253 671).

Install the guide for screw-tapping (ref. 253 678) and the drill sleeve (fig. 19, ref. 253 677). You must check that the guide instruments are correctly positioned using the fluoroscope's oblique view (fig. 20). Bi-cortical drilling using the 2.5mm Ø drill bit (fig. 19, ref. 233 565), and remove the drill guide. Bi-cortical drilling using the 4 mm Ø drill bit (ref. 241 425). Anterior cortical drilling using the 4.5 mm Ø drill bit. Install the cotter pin (fig.21).

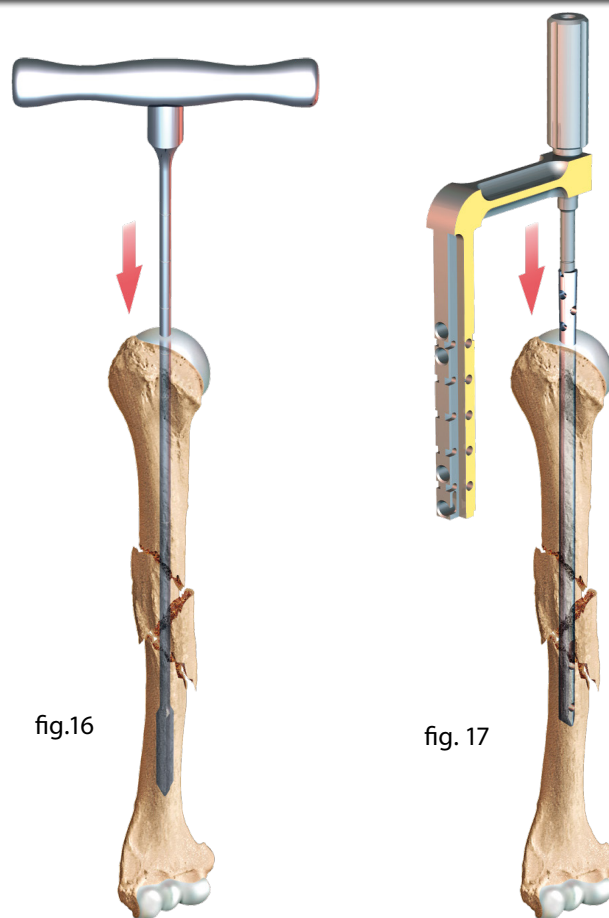


fig.16

fig. 17

If there is a comminutive site, static assembly is recommended. An additional distal cotter screw is installed, following the previous steps. The fluoroscope view is no longer necessary, nor is drilling at 2.5 mm.

3.4 Remark : simplified technique

With experience, it is possible to do the distal locking without installing the intermediate positioner. The oblique view is performed directly. The technique is identical, but without the stages described in chapter 3.2.

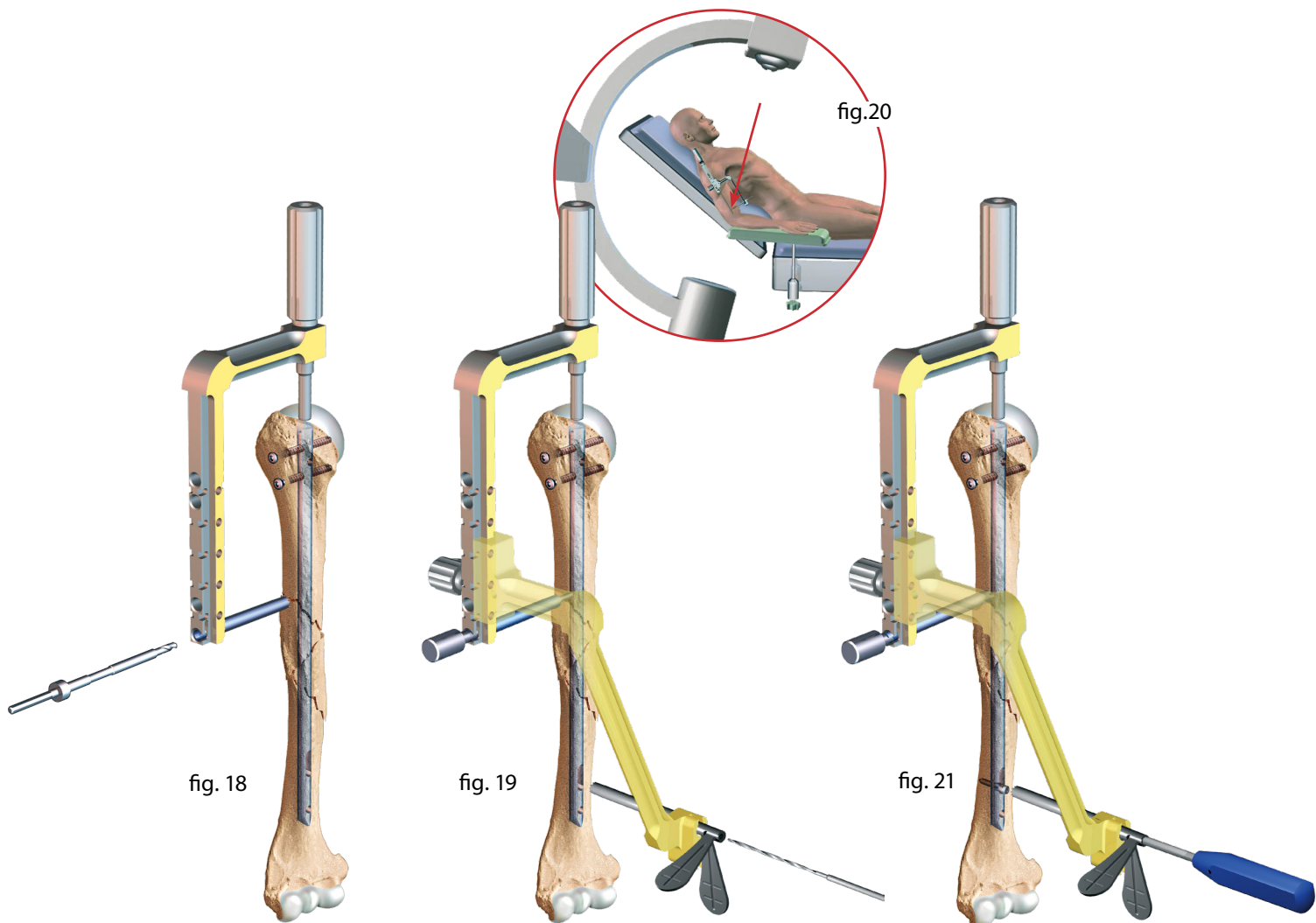


fig. 18

fig. 19

fig. 21

4. REMOVING THE MATERIAL

The TELEGRAPH® should not normally be removed in elderly patients. Two situations can nevertheless result in its removal being necessary:

>> 1. **The screws and/or nail are protruding and causing discomfort.** In this situation, removal will be easy using material that is easy to find.

The installation is still the same (§1.1) with the fluoroscope to do the removal percutaneously.

>> 2. **The patient is young.**

Removal may be difficult if the material is deeply embedded. The installation is the same.

The proximal extremity must be identified: using a metal pin with the fluoroscope makes identification possible. The nail-holder is then positioned on the nail. The guides make it possible to find the screws (fig. 22).

The nail holder is used to find the position of the screws. It should not be used to remove the nail. The nail must be removed with an extractor masselotte with screws on to the M5 connective screw. The masselotte and its axis are optional. If you plan to do removals, you should consider ordering them.

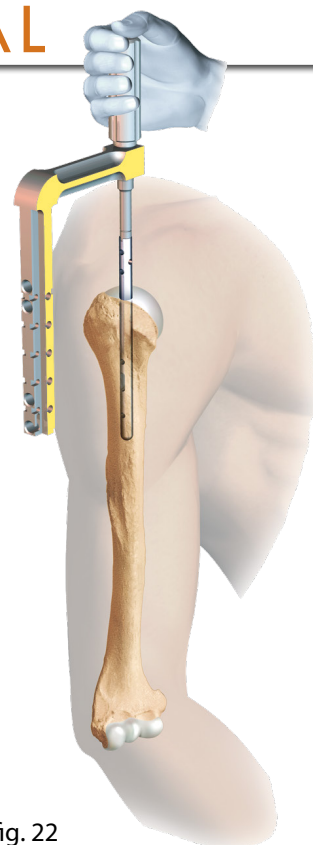
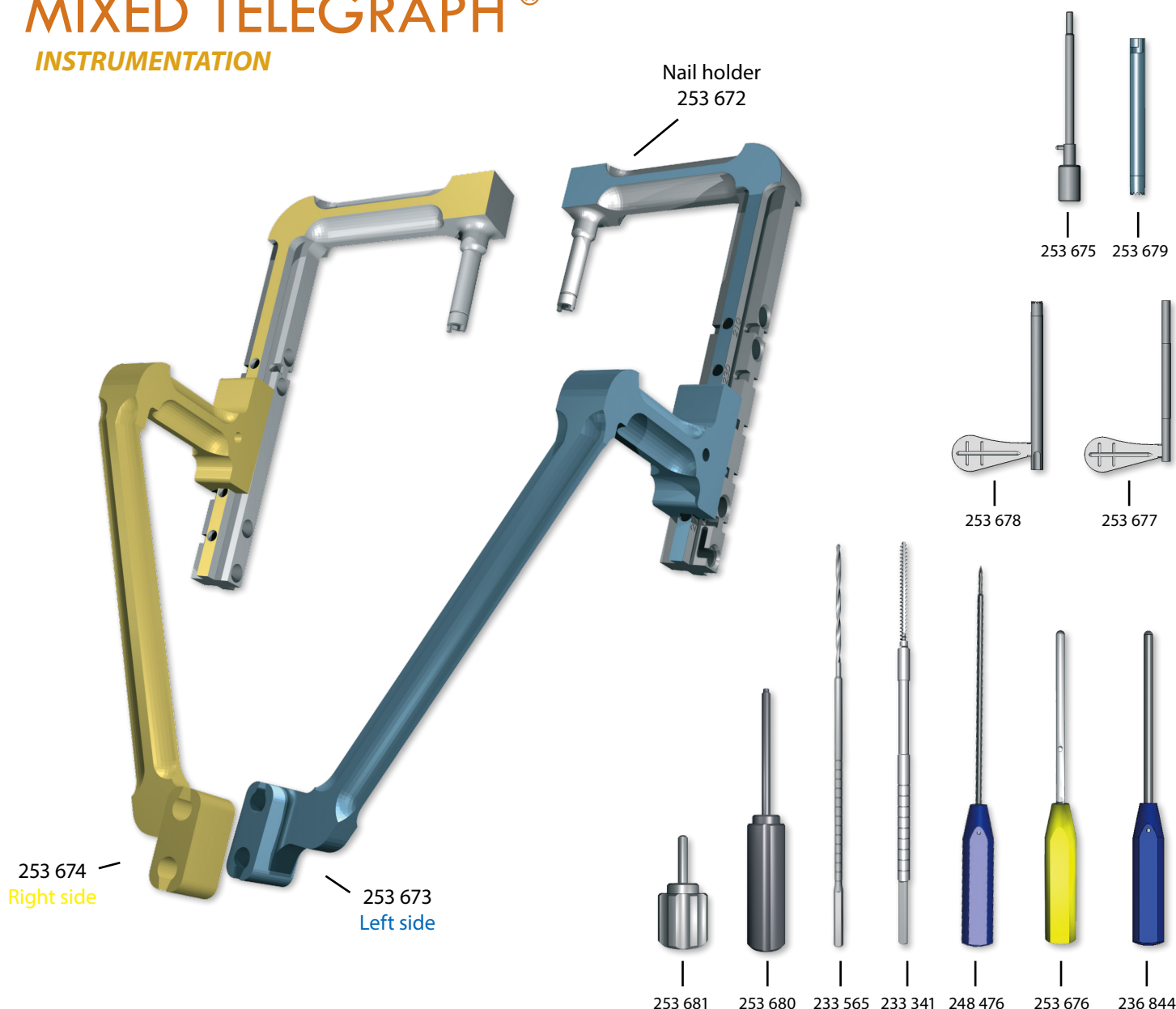


fig. 22

MIXED TELEGRAPH®

INSTRUMENTATION



FH ORTHOPEDICS REFERENCES

REFERENCES	DESIGNATION
233 339	TELEGRAPH® 2.5 screwdriver / flat
233 341	TELEGRAPH® HM screw tap
233 565	2.5 Ø 60 mm long TELEGRAPH® drill bit
236 844	TELEGRAPH® obturator
241 425	4 Ø TELEGRAPH® drill bit
248 476	Long TELEGRAPH® small awl
250 463	MICROSTOP container
250 851	Hand reamer with handle Ø7
250 852	Hand reamer with handle Ø8
250 853	Hand reamer with handle Ø9
253 671	Nail holder
253 672	Proximal targeting device

REFERENCES	DESIGNATION
253 673	Left distal targeting device
253 674	Right distal targeting device
253 675	Intermediate positioner
253 676	Intermediate obturator
253 677	Drilling sleeve, 2.5 Ø drill bit
253 678	Screw-tap sleeve
253 679	Short guide
253 680	M5 connective screw
253 681	M5 screw
253 834	Mixed TELEGRAPH® tray
254 033	4.5 Ø drill bit with abutment
254 160	M5/M3.5 connective screw